

3. On certain Subcutaneous Fat-Bodies in Toads of the Genus *Bufo*. By C. L. BOULENGER, M.A., F.Z.S., King's College, Cambridge.

[Received January 10, 1910.]

(Text-figures 37 & 38.)

I. *Introductory.*

Some little while ago, when engaged in dissecting some African toads of the genus *Bufo*, Mr. E. Degen, F.Z.S., noticed that certain specimens possessed curious gland-like deposits of fat between the skin and ventral body-wall of the abdominal region. He was so kind as to call my attention to these structures, and I came to the conclusion that it would be of interest to more fully investigate this point in Batrachian anatomy.

Examination of specimens of *Bufo regularis* obtained by Dr. Cunningham and myself from the Fayûm province of Egypt showed similar fat-bodies to be present in this species and induced me to examine other allied toads, many of which were found to possess analogous deposits of fat.

I was able to dissect a large number of adequate representatives of various species of *Bufo*. For this my grateful acknowledgments are mainly due to my father, Mr. G. A. Boulenger, F.R.S., who allowed me to examine numerous duplicates from the collections under his care at the British Museum. To Dr. F. Werner, of Vienna, I am indebted for a number of living specimens of the European Green Toad, *Bufo viridis*.

The very rare occurrence of adipose tissue in connection with the muscular system of Batrachia has often been commented on; thus Ant. Dugès (1) in his classical work on the myology and osteology of Batrachians, published in 1835, made the following generalization in his definition of the group:—"Une particularité dès longtemps remarquée c'est l'isolement réciproque des muscles et de la peau, dû à l'absence du pannicule graisseux dont on trouve à peine quelques paquets autour du cou chez les sujets à grand embonpoint."

Corpora adiposa below the skin are, however, not quite unknown.

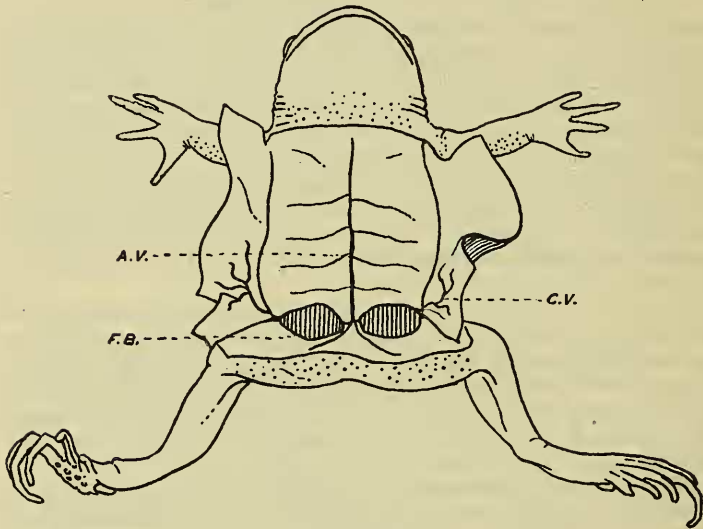
The most recent contribution to our knowledge of this subject is to be found in a paper by F. E. Beddard (7) on the anatomy of the Engystomatid *Hemisus*, the author describing a pair of conspicuous fat-bodies in lymph-sacs in the iliac region. These structures are lobulated masses of fat of considerable size, in

appearance resembling the well-known abdominal fat-bodies at the anterior end of the gonads.

Similar fat-bodies are described as occurring in the neck-region and are probably connected with the thymus glands*.

The following brief remark by Leydig (2) shows that the presence of these bodies in *Bufo* had not escaped the attention of this accomplished investigator, who, however, abstains from any allusion to their structure: "Die Fettkörper in der Achselgrube und Weichengegend waren bei *calamita* rothgelb, bei *variabilis* graugelb, welche Farbenabänderung wohl nur in den verschiedenen Füllung der Blutgefäße gesucht werden darf."

Text-fig. 37.



Bufo viridis, ♀.

Ventral view, with the skin reflected to show the position of the subcutaneous fat-bodies.

F.B. Fat-body. A.V. Ventral abdominal vein. C.V. Cutaneous vein.

* These fat-bodies were noticed by Cope (3) so long ago as 1889, a fact which Mr. Beddard seems to have overlooked. In that author's description of *Hemisus* ('Batrachia of North America' p. 383) we find the following remarks:—

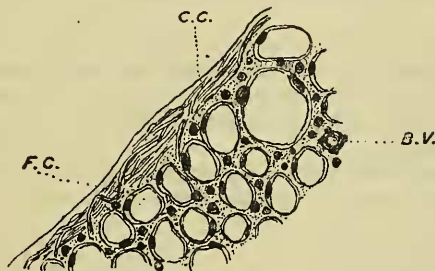
"This genus exhibits also an external corpus adiposum which I have not found in *Callula*, *Engystoma*, or any other genus of Batrachia. Each one is subtriangular, the apex resting near the coracoid, the body lying between the strata of the external and internal oblique muscles"

II. *The Abdominal Fat-Bodies of Bufo viridis.*

The fat-bodies which I am about to describe are very well developed in the common European *Bufo viridis*, fresh material of which I had the opportunity of examining; it will, therefore, be well to preface my remarks with an account of their structure in this form. On reflecting the skin from the ventral surface of a specimen of *B. viridis*, one cannot fail to notice a pair of gland-like, fatty structures at the junction of the hind limbs with the trunk.

These corpora adiposa, which are present in both sexes and vary considerably both in size and colour in different individuals, are quite constant in position; each extends for a considerable distance along the face of the septum inguinale which separates the abdominal and femoral lymph-sacs.

Text-fig. 38.



Bufo viridis, ♀.

Transverse section of part of the subcutaneous fat-body, showing the fat-cells and the connective-tissue capsule. (Obj. $\frac{1}{2}$.)

F.C. Fat-cell. C.C. Connective-tissue capsule. B.V. Blood-vessel.

When fully developed (as in the female specimen figured, text-fig. 37) the fat-bodies are of a bright orange-yellow colour and of considerable thickness. They may extend some distance along the side of the abdomen, their transverse diameter being thus the greatest, attaining a length of nearly 15 mm. In the opposite direction, the width is greatest near the middle line of the body, the body thinning out gradually on the side wall of the abdomen.

The outer free margin of the fat-body is lobulated, the inner side being attached along its whole length to a conspicuous blood-

vessel from which it obtains its blood-supply. This vessel is the vena cutanea femoralis, which runs into the pelvic vein just behind its junction with its fellow from the opposite side to form the ventral abdominal vein.

Sections of the fat-body (text-fig. 38, p. 381) show this organ to consist of an aggregation of fat-cells containing large fat-globules, with enough undifferentiated connective-tissue cells to hold the mass firmly together. Numerous sections of small blood-vessels are to be recognized, and a well-developed connective-tissue capsule surrounds the whole structure.

As mentioned above, the subcutaneous fat-bodies were found to occur in individuals of both sexes; it is, however, necessary to record the fact that these structures, at least in the specimens examined by me, are always better developed and more brilliantly coloured in the females, being somewhat inconspicuous and of a neutral grey colour in the males.

III. *The Fat-bodies in other Species of Bufo.*

Altogether, examples of twenty different species of *Bufo* were cut open and examined, and in fifteen of them fat-bodies were found, identical in structure and in position with those of *Bufo viridis*; in others, as for example the common *B. vulgaris*, no trace of these organs was present.

The complete list of species examined is given below, the forms possessing subcutaneous fat-bodies being marked + :—

+ <i>Bufo andersoni</i> Blgr.	<i>Bufo marinus</i> L.
" <i>asper</i> Gravh.	+ " <i>mauritanicus</i> Schleg.
+ " <i>boreas</i> B. & G.	+ " <i>melanostictus</i> Schneid.
+ " <i>calanita</i> Laur.	+ " <i>pentoni</i> Anders.
+ " <i>carens</i> A. Smith.	+ " <i>raddii</i> Strauchi.
+ " <i>dodsonii</i> Blgr.	+ " <i>regularis</i> Reuss.
+ " <i>granti</i> Blgr.	+ " <i>spinulosus</i> Wieg.
+ " <i>halophilus</i> B. & G.	" <i>tuberosus</i> Gthr.
" <i>latifrons</i> Blgr.	+ " <i>viridis</i> Laur.
+ " <i>lentiginosus</i> Shaw.	" <i>vulgaris</i> Laur.

In addition a number of other tailless Batrachians were examined, including European representatives of the families Hylidæ, Pelobatidæ, and Discoglossidæ: in none of these were fat-bodies to be found at the base of the thighs.

The above list shows that the species of *Bufo* possessing such fat-bodies are not by any means closely related forms; and that this point in Batrachian anatomy is therefore of no great

systematic value. Thus *Bufo latifrons* and *Bufo regularis* are so closely related to one another that some authors refer them to the same species, yet they differ in that the former is devoid of subcutaneous fat-bodies, whereas in the latter these structures are constantly present.

IV. *The Function of the Subcutaneous Fat-Bodies.*

Conspicuous deposits of fat on the ventral abdominal wall are, as is well known, of frequent occurrence in Reptiles (4), and the fat-bodies of *Bufo* described above are similar in certain respects to those found in Lizards on the course of the pelvic and ventral abdominal veins. The latter veins in both Reptiles and in *Bufo* remove the blood from the corpora adiposa and convey it to the liver.

The function of these bodies is difficult to ascertain exactly: they are probably to be regarded as stores of food matter which are drawn upon when necessary. This view is supported by the fact that emaciated specimens have the fat-bodies much reduced, sometimes scarcely visible.

In order to further investigate this point a number of specimens of *Bufo viridis* were kept without food for a considerable time (15 weeks); all showed great reductions in the size of the fat-bodies as compared with those of well nourished specimens.

I mentioned above that the corpora adiposa of this toad were of greater size and contained more fatty matter in the females than in the males; examination of a number of specimens of *B. calamita*, the Natterjack, and of the closely related African form, *B. regularis*, showed this to be correct also of these species. It seems therefore probable that the fat-bodies have also some relation to the reproductive processes, as for example the production of large masses of yolk and albumen for the eggs.

Bibliography.

1. DUGÈS, ANT.—Recherches sur l'Ostéologie et la Myologie des Batraciens. Paris, 1835.
2. LEYDIG, F.—Die Anuren Batrachier der deutschen Fauna. Bonn, 1887.
3. COPE.—The Batrachia of North America. Washington, 1889.
4. BUTLER, G. W.—“On the Relations of the Fat-Bodies of the Sauropsida.” Proc. Zool. Soc. 1889.
5. GIGLIO-TOS, E.—“Sui Corpori grassi degli Anfibi.” Atti Acc. Torino, xxx., 1895.

6. FUNKE, R.—“Ueber die Schwankungen des Fettgehaltes der fettführenden Organe im Kreislauf des Jahres.” Denkschr. Akad. Wien, lxxviii. 1900, p. 595.
7. BEDDARD, F. E.—“Some notes on the muscular and visceral Anatomy of the Batrachian Genus *Hemisus*.” Proc. Zool. Soc. 1908, p. 894.